MS Validated Antibodies GmbH
Bergstedter Chaussee 62a
22395 Hamburg, Germany
Tel: +49 (0) 40 89 72 55 81
E-Mail: info@ms-validatedantibodies.com
Website: ms-validatedantibodies.com

Anti- Bcl-XL Antibody
HMV4724 / Recombinant Rabbit monoclonal

Human SwissProt	Q07817
Human Gene Symbol	BCL2L1
Synonyms	BCL2 like 1 , BCL-XL/S , BCL2L , BCLX , Bcl-X , PPP1R52
Specificity	Bcl-XL
Immunogen	Recombinant human Bcl-XL fragment
Isotype	Rabbit / IgG
Species Reactivity	Human
Localization	Cytoplasmic

Storage & Stability	Antibody with azide – store at 2 to 8 C. Antibody without azide – store at -20 to -80 C. Antibody is stable for 24 months. Non-hazardous. No MSD required.
Supplied As	Purified antibody from Bioreactor Concentrate by Protein A/G. Prepared in 10mM PBS with <1% BSA & <0.1% azide. Antibody concentrate is optimized for dilution within dilution range using commercially available antibody diluent for IHC.
Positive Control	Kidney: A very intense cytoplasmic Bcl-xl staining should be seen in distal tubuli while the staining should be moderate to strong in proximal tubuli.
Negative Control	Lymph node: Bcl-xl staining must be faint or absent in most lymphocytes especially in the interfollicular area.

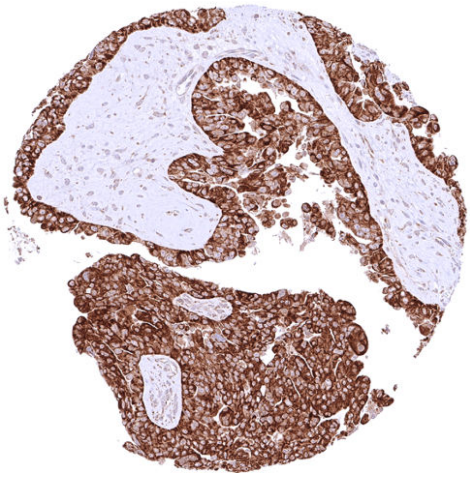

Ovarian serous high-grade carcinoma with intense, cytoplasmic BCL-XL positivity of all tumor cells.

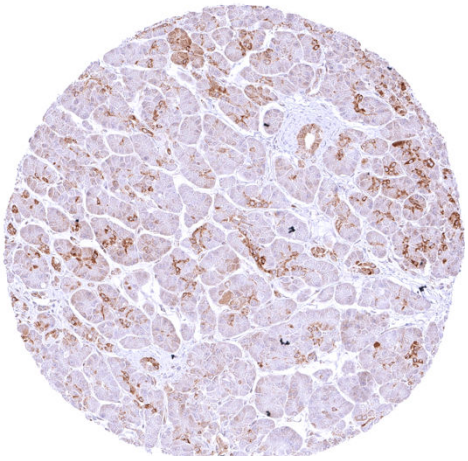

Pancreas with a distinct cytoplasmic BCL-XL staining of intercalated and excretory ducts while staining is weak or absent in acinar cells.

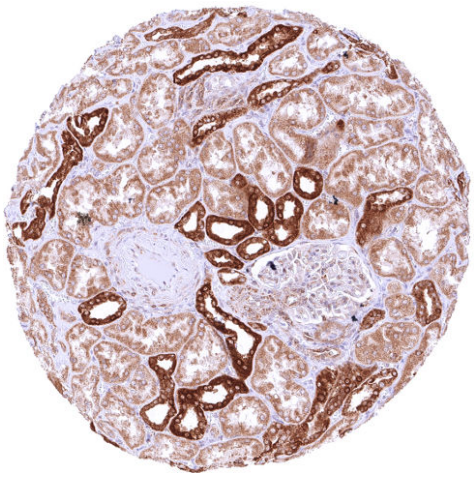

Renal cortex displaying intense BCL-XL staining of distal tubuli while the staining is markedly less but still moderate to strong in proximal tubuli and faint or absent in glomeruli.

Biology

Bcl-xl is an anti-apoptotic member of the BCL-2 protein family representing the long isoform coded by the BCL2L1 gene on chromosome 20q11.21. Bcl-xL localizes to intracellular membranes (primarily the mitochondrial outer membrane) and blocks intrinsic (mitochondrial) apoptosis by binding and sequestering pro-apoptotic BCL-2 family effectors, thereby preventing mitochondrial outer membrane permeabilization, cytochrome c release and caspase activation. Beyond apoptosis inhibition, Bcl-xl affects mitochondrial physiology, cellular metabolism and can modulate autophagy and senescence programs. In mice, constitutive Bcl-xl knockout is embryonic lethal with massive apoptosis of immature neurons and failure of definitive hematopoiesis. Bcl-xl is broadly expressed in many adult tissues and is especially important in cell types with high survival demands such as platelets which depend critically on Bcl-xl for survival. Bcl-xl is frequently upregulated in many cancers and contributes to tumor cell survival, resistance to chemotherapy and targeted agents, maintenance of dormant/senescent tumor cell populations, and metastatic fitness. High Bcl-xl expression has been associated with worse prognosis in selected tumor subgroups. Bcl-xl is a potential anti-cancer target as rather specific inhibitors exist that for example target a large hydrophobic groove involving the BH3 domain, but toxicity to platelets is limiting. Anti Bcl-xl drugs with less effects on platelets are still under investigation.

Potential Research Applications

-What is the clinical significance of Bcl-xl expression levels in cancer?
-Can Bcl-xl expression levels predict response to specific treatments?
-What mechanisms drive acquired resistance to Bcl-xl–directed agents, and how can these be monitored and overcome clinically?
-How does Bcl-xl contribute to persistence of therapy-induced senescent/dormant tumor cells and metastatic seeding, and can transient Bcl-xl targeting eliminate minimal residual disease?

Protocol Suggestions

Dilution: 1:100 – 1:200 ; pH 7,8 is optimal. Freshly cut sections should be used (more than 10 days between cutting and staining deteriorates staining intensity for most antibodies in IHC).

Limitations

This antibody is available for **research use only** and is not approved for use in diagnostics.

Warranty

There are no warranties, expressed or implied, which extend beyond this description. MSVA is not liable for any personal injury or economic loss resulting from this product.

MS Validated Antibodies GmbH
Bergstedter Chaussee 62a
22395 Hamburg, Germany
Tel: +49 (0) 40 89 72 55 81
E-Mail: info@ms-validatedantibodies.com
Website: ms-validatedantibodies.com

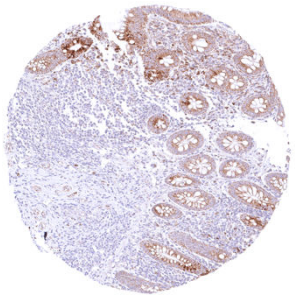

Appendix, mucosa – Distinct cytoplasmic BCL-XL staining of all epithelial cells and a subset of inflammatory cells (plasma cells)

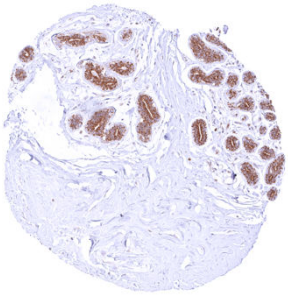

Breast – Moderate to strong cytoplasmic BCL-XL staining of all epithelial cells.

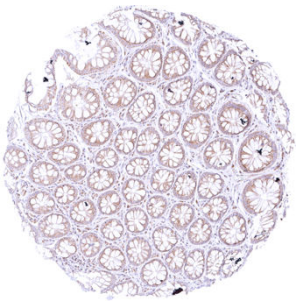

Colon descendens, mucosa – Distinct cytoplasmic BCL-XL staining of all epithelial cells.

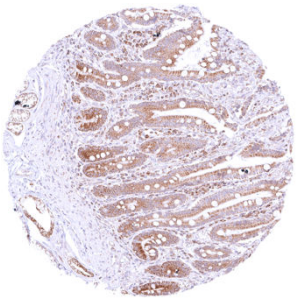

Duodenum, mucosa – Distinct cytoplasmic BCL-XL staining of all epithelial cells and a subset of inflammatory cells (plasma cells).

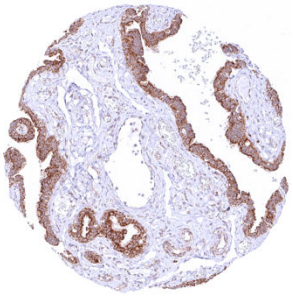

Fallopian tube, mucosa – Strong cytoplasmic BCL-XL staining of epithelial cells.

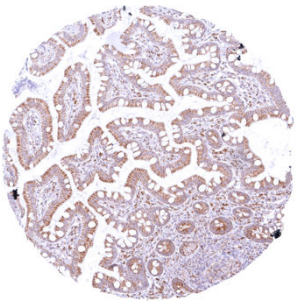

Ileum, mucosa – Distinct cytoplasmic BCL-XL staining of all epithelial cells and a subset of inflammatory cells (plasma cells).

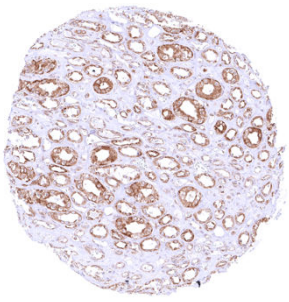

Kidney, medulla – Collecting duct cells show a variable BCL-XL staining ranging from negative to strong.

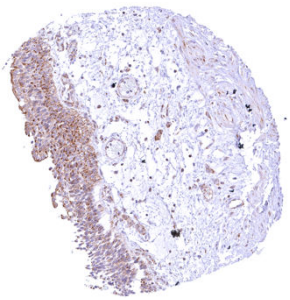

Kidney, pelvis, urothelium – Distinct cytoplasmic BCL-XL staining of urothelial cells.

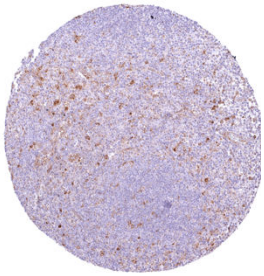

Lymph node – Most lymphocytes, especially in the interfollicular area, are BCL-XL negative or only show a faint staining. Some cell types show a distinct BCL-XL staining, often in germinal centres.

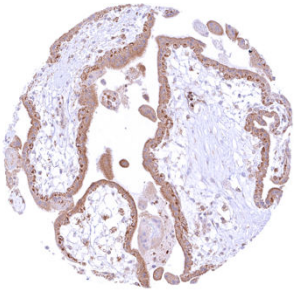

Placenta, early – Strong cytoplasmic BCL-XL staining of trophoblast cells (most intense in the cytotrophoblast).

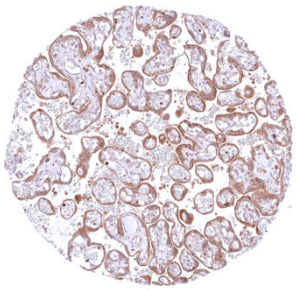

Placenta, mature – Strong cytoplasmic BCL-XL staining of trophoblast cells.

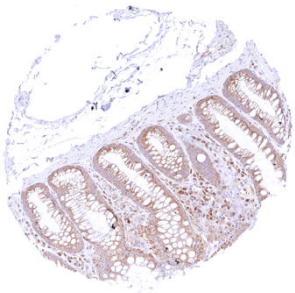

Rectum, mucosa – Distinct cytoplasmic BCL-XL staining of all epithelial cells and a subset of inflammatory cells (plasma cells).

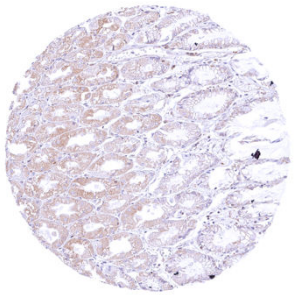

Stomach, corpus – Cytoplasmic BCL-XL staining is moderate in gastric glands but faint in superficial epithelial cells.

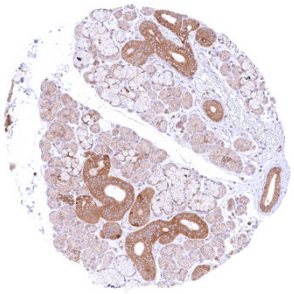

Submandibular gland – Strong cytoplasmic BCL-XL positivity of excretory ducts while the staining is markedly less pronounced in glandular cells.

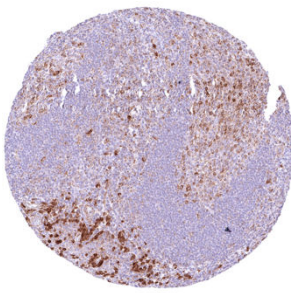

Tonsil – Lymphocytes, especially in the interfollicular zone are largely BCL-XL negative while more BCL-XL staining is seen in germinal centres. Strong BCL-XL positivity of at least one subpopulation of inflammatory cells (plasma cells)

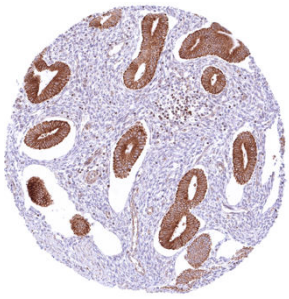

Uterus, endometrium (proliferation) – Strong cytoplasmic BCL-XL staining of endometrial epithelial cells.