MS
Validated Antibodies

MS Validated Antibodies GmbH
Bergstedter Chaussee 62a
22395 Hamburg, Germany
Tel: +49 (0) 40 89 72 55 81
E-Mail:info@ms-validatedantibodies.com
Website: ms-validatedantibodies.com

Anti-Cytokeratin 18 Antibody
MSVA-118 / Mouse monoclonal

Human SwissProt	P05783
Human Gene Symbol	KRT18
Synonyms	Cell Proliferation-inducing Gene 46 Protein; CK18; CYK18Cytokeratin Endo B; K18; Keratin-18; Kerd; KRT18
Specificity	Cytokeratin 18
Immunogen	PMC-42 human breast carcinoma cells
Isotype	Mouse / IgG1,
Species Reactivity	Human
Localization	Cytoplasmic

Storage & Stability	Antibody with azide – store at 2 to 8 C. Antibody is stable for 24 months. Non-hazardous. No MSD required.
Supplied As	Tris Buffer, pH 7,3 – 7,7 with 0.05% BSA & <0.1% azide.
Positive Control	In the liver, an at least weak to moderate predominantly membranous staining should be seen in virtually all hepatocytes. Appendix: a strong staining should be seen in all epithelial cells.
Negative Control	Staining should be absent in non epithelial cells of the appendix and in normal squamous epithelium.

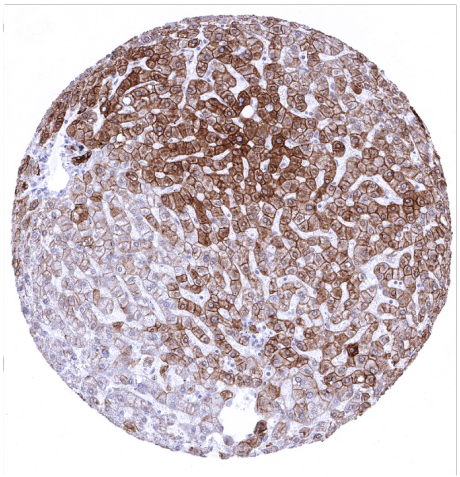

Liver tissue shows a zonal variability of KRT18 expression in hepatocytes ranging from weak to strongly positive while bile ducts are always strongly positive.

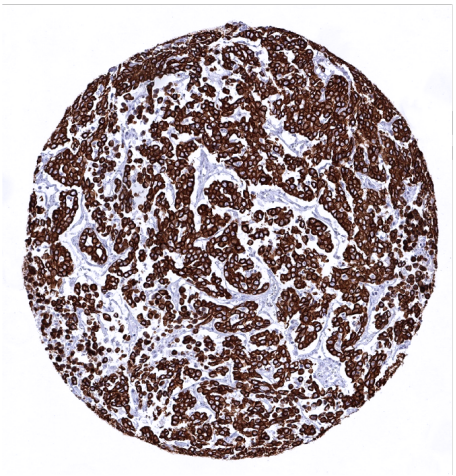

Cholangiocellular carcinoma of the liverwith strong Cytokeratin 18 positivity.

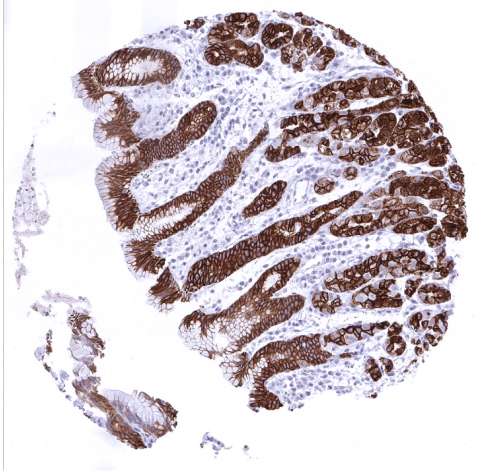

In the stomach mucosa, all epithelial cells except parietal cells of the corpus show strong KRT18 staining.

Biology

Cytokeratin 18 (CK18), also termed keratin 18 (KRT18) is an acidic type I keratin protein encoded by the KRT18 gene on 12q13. It forms heteropolymers with his co-expressed complementary type II keratin partner KRT8. KRT18 is highly expressed in stomach, ileum, appendix, colorectum, gallbladder, pancreas, endocervix, endometrium, pneumocytes of the lung, all tubuli and collecting ducts of the kidney adenohypophysis, and trophoblast cells of the placenta. A strong KRT18 staining of glandular cells is seen in prostate, respiratory epithelium, epididymis, seminal vesicle, and breast glands, while associated basal cells do not show unequivocal staining. Liver tissue shows a zonal variability of KRT18 expression in hepatocytes ranging from weak to strongly positive while bile ducts are always strongly positive. Salivary glands show strong staining of serous and mucinous cells and a somewhat weaker positivity in excretory ducts. Urothelium shows strong KRT18 staining in umbrella cells and a gradual decrease of staining intensity from superficial to basal cells. In lymph nodes, tonsil, spleen, and thymus delicate fibrillar staining caused by CK18 positive fibroblastic reticulum occur mainly in the interfollicular area. In the thymus, corpuscles of Hassall's are partly CK18 positive. KRT18 expression is detectable in many different tumor types. Frequent high level KRT18 expression especially occurs in tumors derived from KRT18 positive normal such as adenocarcinomas of the colorectum, stomach, lung, prostate, pancreas, thyroid as well as ovarian cancer. Tumor types that are mostly KRT18 negative for example include squamous cell carcinomas from various sites of origin, seminomas, and soft tissue tumors. Loss of KRT18 expression in cancers derived from KRT18 expressing precursor cells and upregulation or neo-expression of KRT18 in neoplasias derived from KRT18 negative precursor cells is often linked to unfavorable tumor phenotype and poor patient outcome.

Potential Research Applications

-The diagnostic utility of KRT18 expression analysis should be investigated in a large cohort of tumors from different entities.
-Loss of CK18 expression in tumors derived from CK18 positive progenitor cells and neo-expression of CK18 in tumors derived from CK18 negative progenitor cells have been linked to poor prognosis. The extent of clinical utility of these observations needs further research.

Protocol Suggestions

Dilution: 1:150; pH 7,8 is optimal. Freshly cut sections should be used (less than 10 days between cutting and staining deteriorates staining intensity for most antibodies in IHC).

Limitations

This antibody is available for **research use only** and is not approved for use in diagnostics.

Warranty

There are no warranties, expressed or implied, which extend beyond this description. MSVA is not liable for any personal injury or economic loss resulting from this product.

MS
Validated Antibodies

MS Validated Antibodies GmbH
Bergstedter Chaussee 62a
22395 Hamburg, Germany
Tel: +49 (0) 40 89 72 55 81
E-Mail:info@ms-validatedantibodies.com
Website: ms-validatedantibodies.com

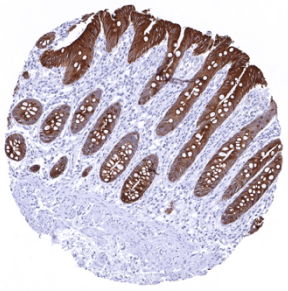

Appendix, mucosa

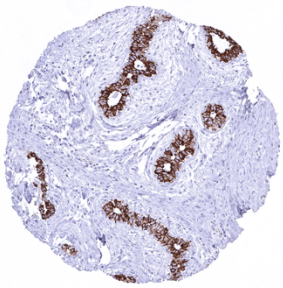

Breast - Luminal cells but not myoepithelial cells stain CK18 positive in normal breast

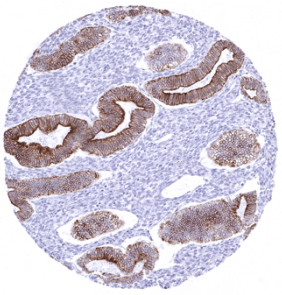

Endometrium, proliferation

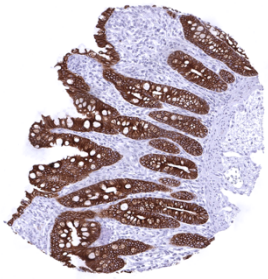

Ileum, mucosa

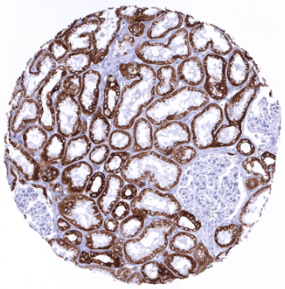

Kidney, cortex

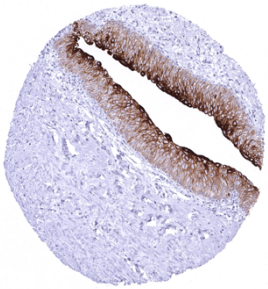

Kidney, pelvis, urothelium - Urothelium stronges staining in umbrella cells and a gradual decrease from the top to the bottom layers of urotheial cells

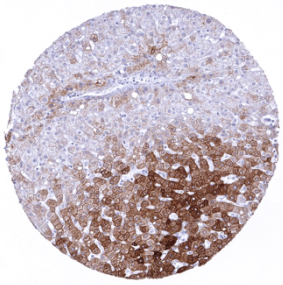

Liver - Not all hepatocytes stain positive for CK18 (zonal distribution)

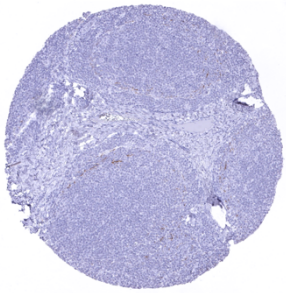

Lymph node - CK18 occurs in fibroblastic reticulum cells of lymhytic organs

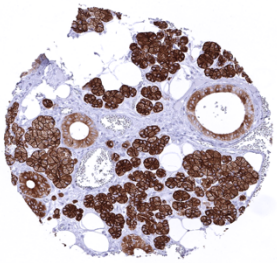

Parotid gland

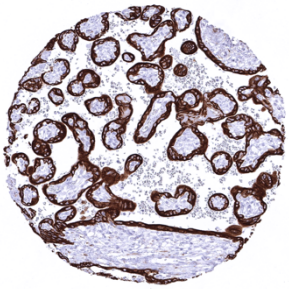

Placenta, mature

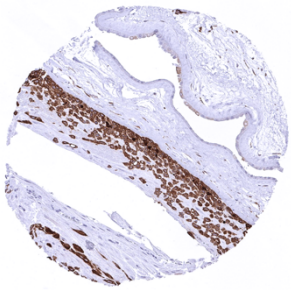

Placenta, mature, amnion and chorion - Strong CK18 staining in chorion cells while the amnion cells are only weakly CK18 positive

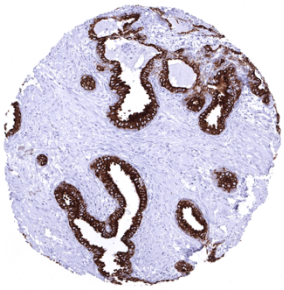

Prostate

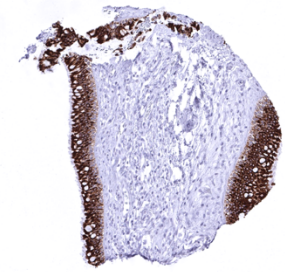

Sinus paranasales

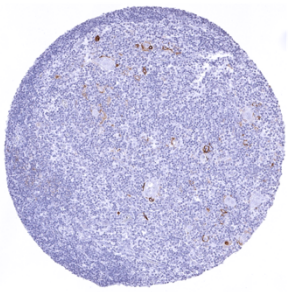

Thymus - Some cellelements of Hassal bodies are CK18 positive

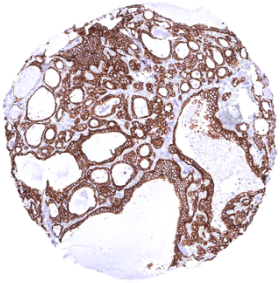

Tyroid gland

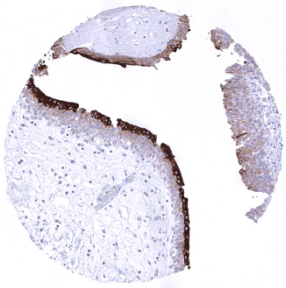

Urinary bladder, urothelium - Urothelium with particularly strong staining in umbrella cells. CK18 staining is weaker in urothelial cells and gradually decreases from the top to the bottom layers