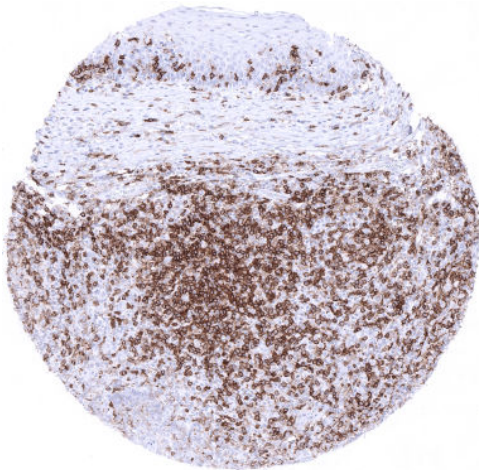


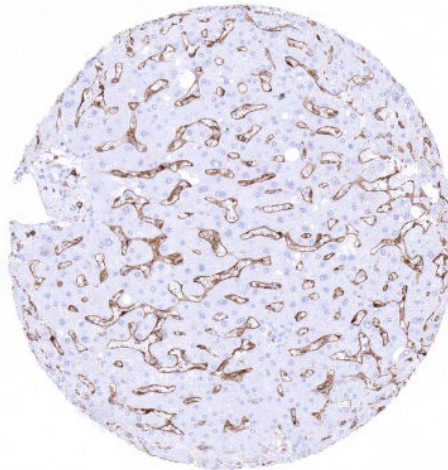
## Anti-CD4 Antibody MSVA-004R / Recombinant Rabbit monoclonal

Human SwissProt	P01730
Human Gene Symbol	CD4
Synonyms	L3T4; Leu3; Ly-4; Lymphocyte antigen CD4; p55; T cell antigen T4/LEU3; T cell differentiation antigen L3T4; T-cell surface antigen T4/Leu-3; T-cell surface glycoprotein CD4
Specificity	CD4
Immunogen	Recombinant human CD4 protein
Isotype	Rabbit / IgG
Species Reactivity	Human
Localization	Cell Surface
Storage & Stability	Antibody with azide – store at 2 to 8 C. Antibody without azide – store at -20 to -80 C. Antibody is stable for 24 months. Non-hazardous. No MSD required.

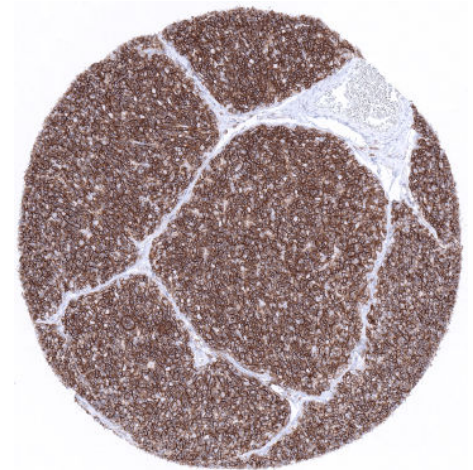
Supplied As	Purified antibody from Bioreactor Concentrate by Protein A/G. Prepared in 10mM PBS with 0.05% BSA & 0.05% azide.
Positive Control	In the liver, an at least weak to moderate staining of sinusoidal endothelial cells should be seen. In the colon, a moderate to strong staining of intraepithelial T- cells should be seen and a fraction of the lymphocytes in the lamina propria should also stain. Macrophages in the germinal centre of the tonsil and lamina propria of the colon mucosa as well as Kupffer cells in the liver should show an at least moderate CD4 positivity.
Negative Control	Epithelial cells should not stain in colon and the tonsil. Hepatocytes must not show staining.



In tonsil tissue, a strong CD4 immunostaining is seen in a fraction of T-cells and in Langerhans cells of the tonsil surface epithelium. Epithelial cells are negative.



Moderate CD4 immunostaining is seen in the sinusoids of the liver.



Virtually all thymocytes of the thymic cortex show intense CD4 immunostaining.

### Biology

CD4 (cluster of differentiation 4; leu-3) is a glycoprotein belonging to the immunoglobulin superfamily which is present on the surface of T helper cells, monocytes, macrophages, and dendritic cells. CD4+ T helper cells are an essential part of the human immune system. One of their main roles is to send signals to other types of immune cells, including CD8 killer cells, which then destroy the infectious particle. CD4 immunostaining is seen in >90% of thymocytes and in a large subset of extrathymic T-lymphocytes which - at variable numbers - can be found in almost every organ/tissue. At a lower level CD4 expression is also seen in monocytes and macrophages. A moderate to strong staining is seen in Langerhans cells of the skin and non-keratinizing squamous epithelium from various sites. Endothelial CD4 positivity is seen at moderate intensity in liver sinusoids. A moderate to strong membranous CD4 positivity is seen in all epithelial cells of the parathyroid gland. Most mature T-cell lymphomas are CD4 positive, while precursor T-lymphoblastic lymphomas show variable CD4 expression. CD4 is also expressed in histiocytic sarcomas and Langerhans cell histiocytosis.

### Potential Research Applications

-CD4 positive cells play a major but not yet fully understood role in inflammation and cancer.

-CD4 is a key component of multicolor assays analyzing the role of lymphocyte subsets in cancers and other diseases.

-The prevalence of a positive CD3 immunostaining in hematological and non-hematological neoplasms should be further evaluated.

### Protocol Suggestions

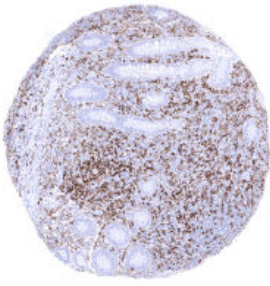
**Dilution: 150; pH 9** is optimal. Freshly cut sections should be used (more than 10 days between cutting and staining deteriorates staining intensity for most antibodies in IHC).

### Limitations

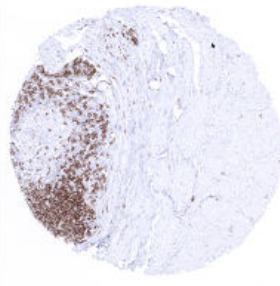
This antibody is available for **research use only** and is not approved for use in diagnostics.

### Warranty

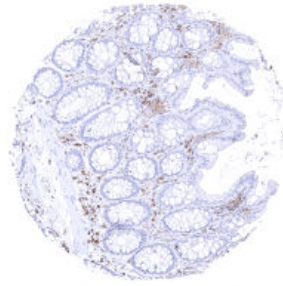
There are no warranties, expressed or implied, which extend beyond this description. MSVA is not liable for any personal injury or economic loss resulting from this product.



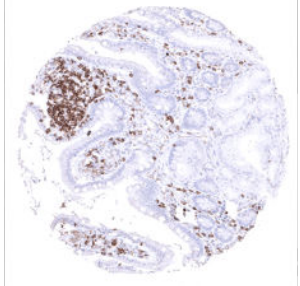
Appendix, mucosa



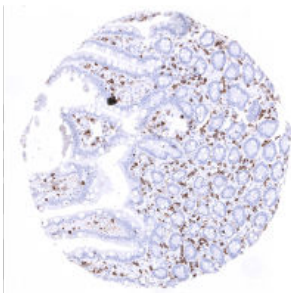
Appendix, muscular wall



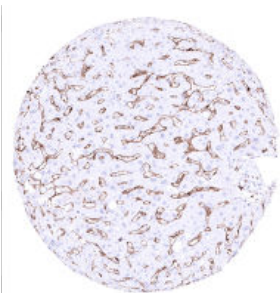
Colon descendens, mucosa



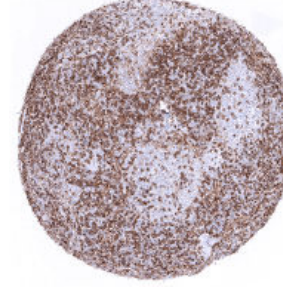Duodenum, mucosa



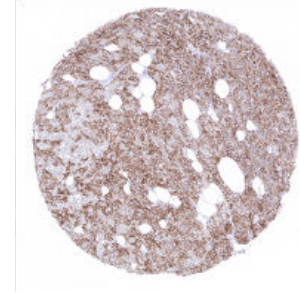
Ileum, mucosa



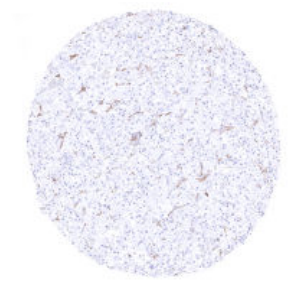
Liver - Endothelial CD4 positivity occurs at moderate intensity in liver sinusoids



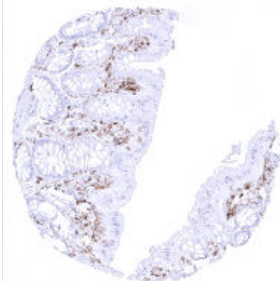
Lymph node - CD4 immunostaining is seen in a large subset of interfollicular T-lymphocytes of lymph nodes



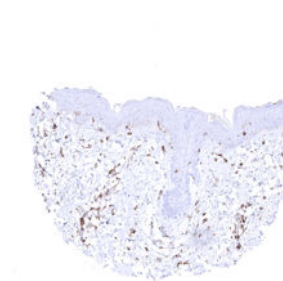
Parathyroid - A moderate to strong membranous CD4 positivity is seen in all epithelial cells of the parathyroid gland



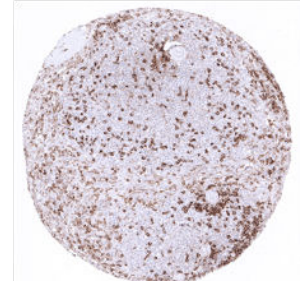
Pituitary, anterior lobe - Endothelial CD4 positivity occurs at low intensity in some small vessels of the adenohypophysis



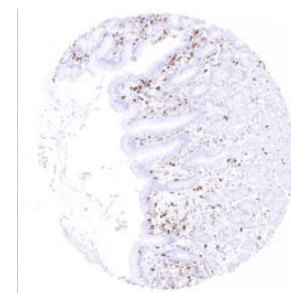
Rectum, mucosa



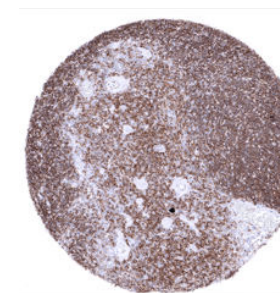
Skin



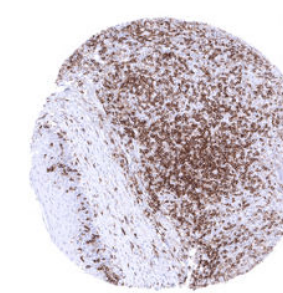
Spleen



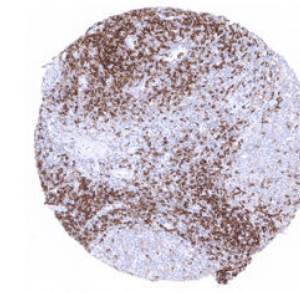
Stomach, corpus



Thymus - In the thymus, CD4 immunostaining is seen in >90% of thymocytes



Tonsil, surface epithelium



Tonsil